



ELSEVIER

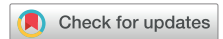Contents lists available at ScienceDirect

The Journal of Arthroplasty

journal homepage: www.arthroplastyjournal.org

Primary Arthroplasty

Distal Femoral Rotation is not Associated With Preoperative Proximal Tibial Varus Angle in Patients With Isolated Medial Compartment Osteoarthritis



Matthew S. Conti, MD, Laura J. Kleeblad, MD, Christopher W. Jones, MD, Andrew D. Pearle, MD, Peter K. Sculco, MD*

Adult Hip and Knee Replacement Service, Hospital for Special Surgery, New York, NY

ARTICLE INFO

Article history:

Received 12 July 2018

Received in revised form

20 September 2018

Accepted 20 September 2018

Available online 28 September 2018

Keywords:

distal femoral rotation
 primary total knee arthroplasty
 preoperative planning
 CT scan measurements
 varus knee

ABSTRACT

Background: Prior studies have found that greater proximal tibial varus was associated with increased external femoral rotation at time of total knee arthroplasty. These works suggest that measuring the tibial plateau-tibial shaft (TPTS) angle on preoperative weight-bearing long leg radiographs could predict significant variations in the posterior condylar angle.

Methods: A minimum of 68 patients were needed to reach 80% power. Patients were included if they had primary medial compartment osteoarthritis and excluded if they had a valgus mechanical axis. The clinical posterior condylar angle (cPCA) was defined as the angle between the anatomic transepicondylar axis and posterior condylar line. Correlation analyses were performed to test for any relationship between the TPTS and cPCA. Two patient groups were created based on TPTS angle: TPTS $\leq 4^\circ$ (mild varus) and TPTS $> 4^\circ$ (moderate varus). Mechanical axis and rotational measurements were compared between the groups using independent *t*-tests.

Results: The mean mechanical axis and TPTS angle were 6.9° and 4.8° of varus, respectively. The mean cPCA was 5.0° (standard deviation [SD], 1.4° ; range, 2.4° - 7.9°). No correlation was found between the TPTS angle and cPCA ($P = .15$). The mean cPCA in the mild varus group ($n = 28$ patients) was 5.2° (SD, 1.5° ; range, 2.7° - 7.9°), and the mean cPCA in the moderate varus group ($n = 45$ patients) was 4.4° (SD, 1.7° ; range, 0.6° - 7.5°). These groups were not statistically significantly different from each other ($P = .62$).

Conclusion: The present study does not support the conclusions of previous works and suggests that the amount of distal femoral rotation cannot be predicted by tibial varus alignment measured on preoperative long leg radiographs. Consequently, we believe that proximal tibial varus should not be used to preoperatively predict external rotation of the femoral component in patients with isolated medial compartment osteoarthritis.

© 2018 Published by Elsevier Inc.

For mechanically aligned total knee arthroplasty (TKA), correct external rotation of the femoral component produces a symmetric flexion gap and optimizes patella tracking [1–5]. Numerous intraoperative anatomic landmarks for femoral component rotation

have been identified including the transepicondylar axis (TEA), the anterior-posterior (AP) axis, and the posterior condylar line (PCL) [6–8]. The femoral component rotation is set parallel to the TEA, perpendicular to the AP axis, and usually 3° externally rotated to the PCL [2], [3], [9], [10]. The benefits and drawbacks of using each of these anatomic landmarks have been extensively investigated, with contradictory data supporting each method. In addition, significant variations in anatomy further add to controversy [1], [2], [5–7], [11–14].

Preoperative radiographic predictors of external femoral rotation have been previously investigated and the proximal tibial varus angle has been associated with the degree of external rotation of the distal femur at time of TKA [2], [3]. Pagnano and Hanssen [3] evaluated the relationship between the tibial plateau-tibial

This work was performed at the Hospital for Special Surgery, New York, NY.

One or more of the authors of this paper have disclosed potential or pertinent conflicts of interest, which may include receipt of payment, either direct or indirect, institutional support, or association with an entity in the biomedical field which may be perceived to have potential conflict of interest with this work. For full disclosure statements refer to <https://doi.org/10.1016/j.arth.2018.09.080>.

* Reprint requests: Peter K. Sculco, MD, Complex Joint Reconstruction Center, Hospital for Special Surgery, New York City, NY 10065.

<https://doi.org/10.1016/j.arth.2018.09.080>

0883-5403/© 2018 Published by Elsevier Inc.

shaft (TPTS) angle measured on weight-bearing hip-knee-ankle (HKA) radiographs and the surgical posterior condylar angle (sPCA) measured intraoperatively, defined as the angle formed between the surgical epicondylar axis (medial epicondylar sulcus to the most prominent point on the lateral epicondyle) and the posterior condylar axis. They found that patients with tibial varus greater than 4° , as measured by the TPTS angle, had an increased likelihood of requiring more distal femoral external rotation at time of TKA [3]. They found a linear relationship between the TPTS and sPCA, although this was not statistically quantified [3]. A subsequent study by Thienpont et al reported that patients with varus alignment of the proximal tibia were more likely to require greater external rotation of the femoral component during TKA surgery [2]. These 2 studies suggest that measuring the TPTS angle on preoperative weight-bearing long leg radiographs could predict significant variations in the posterior condylar angle. This would enable the surgeon to preoperatively predict ideal femoral component rotation during TKA.

The purpose of our study was to use computer tomography (CT) scans in a large cohort of patients with end-stage isolated medial compartment osteoarthritis and evaluate whether an increased TPTS angle correlated with increased distal femoral rotation (PCL to clinical TEA). We hypothesized that (1) increased tibial varus would be a predictor of increased distal femoral rotation and that (2) variations in this relationship may be associated with specific cartilage wear patterns in the degenerative osteoarthritic knee.

Materials and Methods

Study Design and Patient Selection

After institutional review board approval, a sample size calculation was performed based on the cPCA reported in previous studies [3], [12], showing that 68 patients would be needed in the study to reach 80% statistical power. An electronic knee arthroplasty registry search was performed and a total of 73 patients were included. All HKA radiographs and CT scans were available for surgical planning of robotic-arm-assisted unicompartmental knee arthroplasty for primary medial compartment osteoarthritis (RESTORIS MCK Onlay, Stryker Corp, Mahwah, NJ). All surgeries were performed by one of the senior authors over an 8-month period (01/07/2016 until 08/12/2016) using a robotic surgical platform (Mako system, Stryker Corp, Mahwah, NJ). Patients were excluded if they had a valgus mechanical axis. The imaging studies were retrospectively analyzed.

Radiographic Assessment

Radiographic evaluation was performed in a Picture Archiving and Communication System version 16 (PACS; Sectra Imtec AB, Linköping, Sweden). The mechanical axis and TPTS angle were determined using HKA weight-bearing radiographs, and the radiographic technique was standardized for all patients in this cohort and performed by certified radiologic technologists. The TPTS angle was measured using the angle measurement tool on PACS version 16 as illustrated by Pagnano and Hanssen [3] and was the angle formed medially between a line across the tibial plateau connecting the medial and lateral edges of the tibial plateau and line down the center of the tibial shaft.

Patients were instructed to stand straight with extended knees and distribute their body weight evenly. The patellae were aligned with the direction of the X-ray beam. The X-ray beam was centered at the distal pole of the patella, aligning the image parallel to the tibial joint line in the frontal plane. The mechanical axis was defined as the angle between the femoral

mechanical axis (center of the hip to intercondylar notch of the knee) and the tibial mechanical axis (center between tibial spines to center of the distal tibia). The TPTS angle was defined as the proximal medial angle formed between the tibial mechanical axis and the knee joint line of the tibia in the frontal plane [3], [15].

Regarding the CT, measurements were made using the angle measurement tool on PACS version 16, the surgical transepicondylar axis (SEA) was defined as the sulcus on the medial side and the most prominent point on the lateral epicondyle. The anatomic transepicondylar axis (AEA) was constructed on axial CT scans as a line between the medial and lateral epicondyles. The PCL was the tangent line from the posterior bony edge of the medial to the lateral condyles. The angles between the SEA or AEA and the PCL were defined as the sPCA ($sPCA = PCL - SEA$) and the clinical posterior condylar angle (cPCA = $PCL - AEA$) (Fig. 1), respectively [2], [3]. Measurements on CT scans were taken using the technique described above by 2 independent observers. We chose to use the cPCA in order to assess rotational alignment of the femur as a previous study demonstrated that more significant osteoarthritis made detecting the medial sulcus as required in the sPCA measurement to be unreliable [16]. Yoshino et al [16] concluded that the cPCA should be used to measure distal femoral rotation in arthritic knees and that the sPCA can be approximated by subtracting 3° from the cPCA.

To test our second hypothesis, femoral wear patterns were categorized on weight-bearing AP and posteroanterior (PA) flex radiographs of the affected knee. Patients were grouped into 3 cohorts based on their wear patterns. The first group consisted of patients with degenerative changes more distally on the femoral condyle, showing severe medial wear on the AP radiograph and minimal medial wear on the PA flex view. Group 2 had more posterior medial femoral condyle wear, which was demonstrated by severe medial wear on the PA flex view with minimal wear on the AP radiograph. The third group had severe wear on both the PA flex and AP views. Two independent researchers reviewed all radiographs for all patients, based on the wear pattern assigned to 1 of the 3 groups.

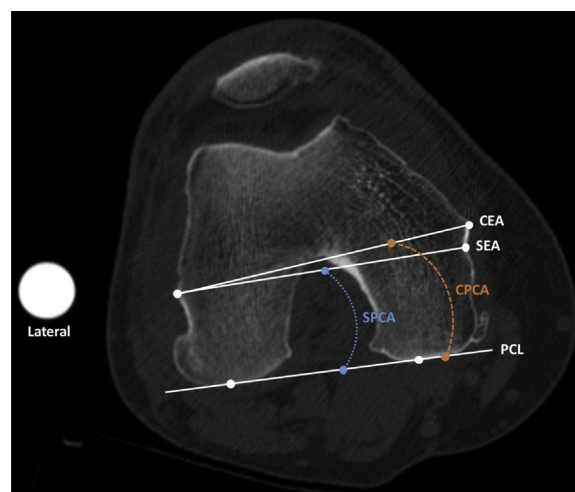


Fig. 1. Surgical and clinical posterior condylar angles. The surgical posterior condylar angle (sPCA) is the angle between the posterior condyle line (PCL), which connects the most posterior aspects of the medial and lateral femoral condyles, and surgical epicondylar angle (SEA), which is a line from the lateral epicondyle to the medial sulcus. The clinical posterior condylar angle (cPCA) is the angle between the PCL and the clinical epicondylar axis (CEA), which connects the medial and lateral distal femoral epicondyles.

Table 1
Patient Characteristics and Average Preoperative Alignment of Patients Included in the Study.

Descriptive Statistic	Patient Characteristics	Standard Deviation	Range
Number of CT scans	73 Patients		
Male/female patients	39 Men (53.4%)/ 34 women (46.6%)		
Average age	61.3 y	9.0 y	41.4–87.5 y
Preoperative mechanical alignment	6.9° Varus	3.1° Varus	0.0°–17.3° Varus
Preoperative TPTS	4.8° Varus	2.1° Varus	0.2°–10.0° Varus
Preoperative mLDFA	88.2°	2.0°	83.3°–93.8°

CT, computed tomography; TPTS, tibial plateau-tibial shaft; mLDFA, mechanical lateral distal femoral angle.

Statistical Analysis

All analyses were conducted using SPSS version 24 (SPSS Inc, Armonk, NY). Descriptive analyses were reported using means, standard deviations (SD), and ranges for continuous variables and frequencies with percentages for discrete variables. Intraobserver and interobserver reliability measurements were assessed by 2 independent observers for all 73 patients. They were blinded to each other's results. For the intraobserver reliability, the measurements were taken on 2 occasions 4 weeks apart. In addition, interobserver reliability was measured between 2 independent observers which assessed the femoral wear patterns. A 2-way mixed model was used, single measures were displayed for intraobserver reliabilities and average measures for interobserver reliabilities, which were defined as interclass correlation coefficients (ICCs) [17]. Furthermore, Pearson correlation analyses were performed in SPSS to test for any relationship between the TPTS and cPCA. Finally, based on the study by Pagano and Hansson (2001) [3], 2 patient groups were created based on TPTS angle: TPTS $\leq 4^\circ$ and TPTS $> 4^\circ$. Mechanical axis and rotational measurements were compared between the groups using independent *t*-tests, after the data were checked for normal distribution using the Shapiro-Wilk test.

Results

Seventy-three patients with preoperative HKA radiographs and preoperative CT scans were included in this study. The average age

was 61.3 years (SD, 9.0; range, 41.4–87.5). Thirty-nine patients (53.4%) were male, and 34 patients (46.6%) were female (Table 1). The mean mechanical axis was 6.9° of varus (SD, 3.1°; range, 0.0°–17.3°). The mean TPTS angle was 4.8° of varus (SD, 2.1°; range, 0.2°–10°) with an interobserver reliability (ICC) of 0.92 (95% confidence interval [CI], 0.87–0.95; Table 1).

The mean sPCA was 2.6° (SD, 1.3°; range, 0.0°–5.5°). The mean cPCA was 5.0° (SD, 1.4°; range, 2.4°–7.9°). The corresponding cPCA intraobserver and interobserver ICCs were found to be 0.94 (95% CI, 0.85–0.97) and 0.57 (95% CI, 0.11–0.79), respectively. This demonstrates excellent intraobserver reliability and moderate reliability of the interobserver measurements. No correlation was found between the TPTS angle and cPCA ($P = .15$; Fig. 2).

Based on the Pagnano and Hanssen's article [3], the patients were then divided into 2 groups: those with a TPTS angle $\leq 4^\circ$ (mild varus, $n = 28$ patients) and those with TPTS angle $> 4^\circ$ (moderate varus, $n = 45$ patients). In the mild varus group, the mean mechanical axis was 5.3° of varus (SD, 2.2°; range, 0°–11.7°), and TPTS angle was 2.8° (SD, 1.0°; range, 0.2°–3.8°). The mean cPCA was 5.2° (SD, 1.5; range, 2.7°–7.9°). The moderate varus group (TPTS $> 4^\circ$) had a mean mechanical axis of 7.9° (SD, 3.2°; range, 1.0°–17.3°) and mean TPTS angle of 6.1° (SD, 1.6°; range, 4.1°–10.6°). The mean cPCA of this group was 4.4° (SD, 1.7°; range, 0.6°–7.5°), which was not statistically different than the mild varus group ($P = .62$; Table 2).

Furthermore, wear patterns were evaluated (Table 3), and pattern 3 was found to be most prevalent ($n = 36$, 49.3%) compared to pattern 1 ($n = 18$, 24.7%) or pattern 2 ($n = 19$, 26.0%) (Table 3). Interobserver reliability for the wear patterns had an ICC of 0.91 (95% CI, 0.863–0.946), which suggests excellent correlation between the reviewers. The TPTS was statistically different between the different wear patterns, specifically patients with pattern 1 had a lower TPTS than patterns 2 and 3 ($P = .046$ and $P = .017$, respectively; Table 3). No differences in cPCA were observed between the 3 groups.

Discussion

This study demonstrates that distal femoral rotation does not correlate with tibial varus in patients with a varus mechanical axis and isolated medial compartment osteoarthritis, and this work is the first to examine preoperative distal femoral rotation in patients indicated for a unicompartmental knee arthroplasty. These results do not support previous work by Pagnano and Hanssen [3] and Thienpont et al [2] demonstrating a correlation between tibial

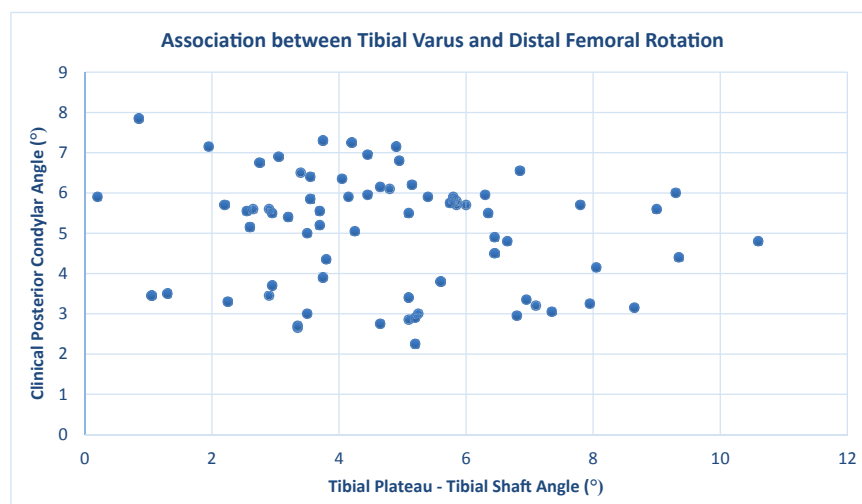


Fig. 2. Association between tibial varus and distal femoral rotation. Distal femoral rotation was measured by the clinical posterior condylar angle (cPCA). As demonstrated in the graph above, there was no association between the cPCA and tibial plateau-tibial shaft angle ($P = .15$).

Table 2
Mean Values by Tibial Plateau-Tibial Shaft Angle Group.

Radiographic Measurements	TPTS $\leq 4^\circ$ (Mild Varus)	TPTS $> 4^\circ$ (Moderate Varus)
Mean TPTS	2.8° (SD, 1.0°; range, 0.2°–3.8)	6.1° (SD, 1.6°; range, 4.1°–10.6)
Mean mechanical axis	5.5° (SD, 2.5°; range, 0°–11.7°)	7.8° (SD, 3.1°; range, 1.0°–17.3°)
Mean cPCA; P value = .62	5.2° (SD, 1.5°; range, 2.7°–7.9°)	4.4° (SD, 1.7°; range, 0.6°–7.5°)

There was no significant difference in the mean external rotation of the distal femur as measured by the cPCA between the 2 groups ($P = .62$). TPTS, tibial plateau-tibial shaft; SD, standard deviation; clinical posterior condylar angle.

varus and external rotation of the distal femur. The primary difference between our work and previous studies was that we chose to limit our study population to patients with a varus mechanical axis and isolated medial compartment osteoarthritis in order to determine whether the relationship between distal femoral rotation and tibial varus held in this subset of patients, which may behave differently than a TKA cohort. However, these results may be more generalizable to patients with varus deformity and isolated medial compartment osteoarthritis who are being considered for a TKA as one of the senior surgeons at our institution would treat these patients with a TKA in his practice.

Implant position of the femoral component during TKA surgery can be influenced by the variability in a patient's native distal femur rotation. To ensure a symmetrically balanced flexion gap and correct patellar tracking, it is important to determine the degree of external rotation of the distal femur and preferably to be able to define this preoperatively. Berger et al [1] were the first to define the sPCA as 3.5° (SD, 1.2°) in men and 0.3° (SD, 1.2°) in women in a group of 75 cadaver specimens. Previous studies have reported that the average sPCA is variable, between 1.3° and 4° [2], [3], [5], [12], [18]. The average cPCA has been reported to be about 3.5° to 7.0° [5], [12], [16].

Pagnano and Hanssen [3] measured the preoperative TPTS angle on long leg radiographs and intraoperative PCA using the SEA in 60 patients indicated for TKA. They found an average sPCA of 3.98° [3]. Patients with a TPTS angle $> 3.3^\circ$ had, on average, a statistically significantly greater sPCA [3]. Additionally, Pagnano and Hanssen [3] reported that the correlation between the TPTS angle and sPCA was readily apparent, but did not provide a correlation coefficient or report statistical significance. This study was limited by the sPCA being measured by only 1 observer intraoperatively, which could lead to significant measurement error. Previous studies have also described a high variability in intraoperative measurements of the TEA with intraobserver ICCs between 0.50 and 0.71 and an interobserver ICC of 0.18 [13], [14].

Another study by Thienpont et al [2] reviewed 2637 CT scans and assessed rotation of the distal femur in preparation for femoral

Table 3
Tibial Plateau-Tibial Shaft Angle (TPTS) and Clinical Posterior Condylar Angle (cPCA) by Distal Femoral Wear Pattern.

Distal Femoral Wear Pattern	TPTS	cPCA
Pattern 1	3.8 (SD, 1.4)	4.9 (SD, 1.7)
Pattern 2	5.2 (SD, 2.4)	5.4 (SD, 1.3)
Pattern 3	5.1 (SD, 2.1)	4.9 (SD, 1.4)
	$P = .042^*$	$P = .413$

Asterisk indicates statistical significance.

Post hoc testing demonstrated that patients with pattern 2 ($P = .046$) and pattern 3 ($P = .017$) distal femoral wear (ie, more severe posteromedial condyle wear on the posteroanterior flex view) had significantly greater TPTS than patients with isolated medial condyle wear on the anteroposterior view. SD, standard deviation.

axial alignment during TKA. The mean sPCA as measured from the PCL to the SEA was 4° [2]. In a multivariate model, they found that tibial varus was significantly correlated with mean external rotation, mechanical axis, and patient age [2]. However, the clinical implication of this was unclear as the mean difference in external rotation was only 0.3° and no minimal clinically important difference was calculated. The authors reported that patients with 1°–2° of tibial varus had a mean external rotation of -3.9° whereas those with 5°–16° of tibial varus had a mean external rotation of -4.2° [2].

The present study does not support the work of Pagnano and Hanssen [3] or the conclusions drawn by Thienpont et al [2]. In our work, the average cPCA in varus knees was 5.2° (SD, 1.5°) in patients with TPTS angle $\leq 4^\circ$ and 4.4° (SD, 1.7°) in patients with a TPTS angle $> 4^\circ$. There was no statistically significant difference in the rotation of the native distal femur between the 2 groups, and no significant correlation was found between the cPCA and the TPTS angle measured on preoperative standing radiographs. Based on our work as well as the small clinically insignificant difference found by Thienpont et al [2], tibial varus seems to be a poor predictor to assess variations in distal femoral rotation.

Our cohort consisted of patients with medial compartment osteoarthritis, which was thought to influence the correlation between TPTS and cPCA. We anticipated that patients with a TPTS greater than their cPCA would have more distal femoral wear than posterior medial femoral condyle wear. However, the location of the degenerative changes on the femoral condyle did not account for the differences found between our study and the previous literature. No differences in cPCA were found between the 3 wear patterns, only the tibial varus angle of pattern 1 was significantly lower than patterns 2 and 3. Therefore, in our study, different patterns of distal and posterior medial bone loss could not account for our finding that distal femoral rotation was not correlated with varus and valgus alignment of the proximal tibial on weight-bearing radiographs.

One weakness of our study was the small sample size compared with previously published reports on distal femoral rotation. Additionally, the CT scans used in this study did not have residual cartilage medially, which has been shown to affect calculation of the posterior condylar angle [6], [7].

In conclusion, this study showed that the amount of distal femoral rotation in patients with isolated medial compartment osteoarthritis cannot be predicted by tibial varus alignment measured on preoperative long leg radiographs. This conflicts with the previously published work by Pagnano and Hanssen [3]. This study suggests that the amount of varus alignment of the proximal tibia is not related to the amount of distal femoral rotation and, consequently, long leg radiographs and proximal tibial varus cannot be used to preoperatively predict which patients with isolated medial compartment osteoarthritis may require more external rotation of the femoral component during TKA. Alternative radiographic predictors should be investigated that more reliably predict accurate rotation of the femoral component.

References

- [1] Berger RA, Crossett LS, Jacobs JJ, Rubash HE. Malrotation causing patellofemoral complications after total knee arthroplasty. *Clin Orthop Relat Res* 1998;356:144–53.
- [2] Thienpont E, Schwab P-E, Paternostre F, Koch P. Rotational alignment of the distal femur: anthropometric measurements with CT-based patient-specific instruments planning show high variability of the posterior condylar angle. *Knee Surg Sports Traumatol Arthrosc* 2014;22:2995–3002. <https://doi.org/10.1007/s00167-014-3086-2>.
- [3] Pagnano MW, Hanssen AD. Varus tibial joint line obliquity: a potential cause of femoral component malrotation. *Clin Orthop Relat Res* 2001;392:68–74.
- [4] Wright SJ, Boymans TAEJ, Grimm B, Miles AW, Kessler O. Strong correlation between the morphology of the proximal femur and the geometry of the

- distal femoral trochlea. *Knee Surgery, Sport Traumatol Arthrosc* 2014;22:2900–10. <https://doi.org/10.1007/s00167-014-3343-4>.
- [5] Aglietti P, Sensi L, Cuomo P, Ciardullo A. Rotational position of femoral and tibial components in TKA using the femoral transepicondylar axis. *Clin Orthop Relat Res* 2008;466:2751–5. <https://doi.org/10.1007/s11999-008-0452-8>.
- [6] Asada S, Akagi M, Matsushita T, Hashimoto K, Mori S, Hamanishi C. Effects of cartilage remnants of the posterior femoral condyles on femoral component rotation in varus knee osteoarthritis. *Knee* 2012;19:185–9. <https://doi.org/10.1016/j.knee.2011.02.008>.
- [7] Fujii T, Kondo M, Tomari K, Kadoya Y, Tanaka Y. Posterior condylar cartilage may distort rotational alignment of the femoral component based on posterior condylar axis in total knee arthroplasty. *Surg Radiol Anat* 2012;34:633–8. <https://doi.org/10.1007/s00276-012-0950-y>.
- [8] Middleton FR, Palmer SH. How accurate is Whiteside's line as a reference axis in total knee arthroplasty? *Knee* 2007;14:204–7. <https://doi.org/10.1016/j.knee.2007.02.002>.
- [9] Olcott CW, Scott RD. A comparison of 4 intraoperative methods to determine femoral component rotation during total knee arthroplasty. *J Arthroplasty* 2000;15:22–6.
- [10] Griffin FM, Insall JN, Scuderi GR. The posterior condylar angle in osteoarthritic knees. *J Arthroplasty* 1998;13:812–5.
- [11] Griffin FM, Math K, Scuderi GR, Insall JN, Poilvache PL. Anatomy of the epicondyles of the distal femur: MRI analysis of normal knees. *J Arthroplasty* 2000;15:354–9.
- [12] Victor J. Rotational alignment of the distal femur: a literature review. *Orthop Traumatol Surg Res* 2009;95:365–72. <https://doi.org/10.1016/j.otsr.2009.04.011>.
- [13] Jenny J-Y, Boeri C. Low reproducibility of the intra-operative measurement of the transepicondylar axis during total knee replacement. *Acta Orthop Scand* 2004;75:74–7. <https://doi.org/10.1080/00016470410001708150>.
- [14] Jerosch J, Peuker E, Philipps B, Filler T. Interindividual reproducibility in perioperative rotational alignment of femoral components in knee prosthetic surgery using the transepicondylar axis. *Knee Surg Sports Traumatol Arthrosc* 2002;10:194–7. <https://doi.org/10.1007/s00167-001-0271-x>.
- [15] Cooke TD, Pichora D, Siu D, Scudamore RA, Bryant JT. Surgical implications of varus deformity of the knee with obliquity of joint surfaces. *J Bone Joint Surg Br* 1989;71:560–5.
- [16] Yoshino N, Takai S, Ohtsuki Y, Hirasawa Y. Computed tomography measurement of the surgical and clinical transepicondylar axis of the distal femur in osteoarthritic knees. *J Arthroplasty* 2001;16:493–7. <https://doi.org/10.1054/arth.2001.23621>.
- [17] Weir JP. Quantifying test-retest reliability using the intraclass correlation coefficient and the SEM. *J Strength Cond Res* 2005;19:231–40. <https://doi.org/10.1519/15184.1>.
- [18] Park A, Nam D, Friedman MV, Duncan ST, Hillen TJ, Barrack RL. Inter-observer precision and physiologic variability of MRI landmarks used to determine rotational alignment in conventional and patient-specific TKA. *J Arthroplasty* 2015;30:290–5. <https://doi.org/10.1016/j.arth.2014.08.015>.