



Contents lists available at ScienceDirect

The Journal of Arthroplasty

journal homepage: www.arthroplastyjournal.org

Complications - Infection

Barbed Suture Is Associated With Increased Risk of Wound Infection After Unicompartmental Knee Arthroplasty

Harshvardhan Chawla, BS^{a,*}, Jelle P. van der List, MD^a, Nicole B. Fein, PA-C^a, Michael W. Henry, MD^b, Andrew D. Pearle, MD^a^a Computer Assisted Surgery Center, Department of Orthopedic Surgery, Hospital for Special Surgery, Weill Cornell Medical College, New York, New York^b Division of Infectious Disease, Department of Medicine, Hospital for Special Surgery, Weill Cornell Medical College, New York, New York

ARTICLE INFO

Article history:

Received 15 October 2015

Received in revised form

8 January 2016

Accepted 11 January 2016

Available online 22 January 2016

Keywords:

barbed suture

Quill

unicompartmental knee arthroplasty

infection

dehiscence

complications

ABSTRACT

Background: Literature addressing the risks of barbed suture in arthroplasty remains limited. No study to our knowledge has compared rates of wound infection between barbed and conventional suture after unicompartmental knee arthroplasty (UKA). We hypothesized that barbed suture would be associated with an increased risk of wound infection in patients undergoing UKA.

Methods: Electronic records were retrieved for 1040 UKA procedures. Odds ratios with postoperative wound infection as the outcome and barbed suture as the exposure were calculated. Binary logistic regression corrected for age, gender, body mass index, operative time, and risk factors (smoking, diabetes, renal insufficiency, and immunosuppression). Barbed suture consisted of Quill #2 polydioxanone (or #0 Vicryl) for deep closure and Quill 2-0 Monoderm for subcuticular closure. Conventional suture consisted of #0 Vicryl for deep closure and subcuticular 2-0 Monocryl or staples for skin closure.

Results: A total of 839 procedures were included. Barbed suture was used in 333 surgeries, and conventional suture was used in 506. Eight cases of postoperative wound infection were identified. All infections occurred in the barbed suture cohort. Regression analysis revealed an association between subcuticular barbed suture and postoperative wound infection (odds ratio = 22.818, confidence interval = 2.69–2923.91; $P = .0074$).

Conclusions: The findings indicate that the use of barbed suture in subcuticular layer closure is associated with an increased risk of wound infection. This may be exacerbated by early intensive mobilization, commonly undertaken after UKA to permit rapid functional return. We recommend against the use of barbed suture for subcuticular layer closure in UKA.

© 2016 Elsevier Inc. All rights reserved.

Barbed suture has been used in plastic, general, and urogynecologic procedures with favorable results [1–5]. However, the suitability and safety profile of barbed suture for arthroplasty remain unclear. Existing studies are limited in number and often nonuniform with regard to the procedures performed [2,6–14]. Reported complications vary by series, resulting in a lack of overall consensus with respect to the risks of this technology in joint arthroplasty [2,6–14].

One or more of the authors of this paper have disclosed potential or pertinent conflicts of interest, which may include receipt of payment, either direct or indirect, institutional support, or association with an entity in the biomedical field which may be perceived to have potential conflict of interest with this work. For full disclosure statements refer to <http://dx.doi.org/10.1016/j.arth.2016.01.007>.

* Reprint requests: Harshvardhan Chawla, BS, Hospital for Special Surgery, 535 East 70th Street, New York, NY 10021.

<http://dx.doi.org/10.1016/j.arth.2016.01.007>

0883-5403/© 2016 Elsevier Inc. All rights reserved.

The literature is particularly sparse concerning the use of barbed suture in unicompartmental knee arthroplasty (UKA). Only 1 study has included patients undergoing UKA in combination with patients undergoing total knee arthroplasty (TKA) [2]. The authors reported higher wound complication rates when closing with V-Loc barbed suture, prompting discontinuation of its use [2]. A need, therefore, exists for (1) studies evaluating the risks of barbed suture in UKA exclusively and (2) a consolidated review of prior studies addressing barbed suture in arthroplasty.

To our knowledge, no study to date has compared complication rates between barbed and conventional suture in a standardized population of patients undergoing UKA. The aim of this study was to determine if barbed suture confers a greater risk of postoperative wound infection after UKA. We hypothesized that barbed suture would be associated with an increased risk of wound infection in a large standardized population of patients undergoing UKA.

Materials and Methods

Enrollment

After institutional review board approval, records were retrieved for 1040 robot-assisted UKA procedures between June 2007 and August 2015. Patients were required to fulfill the criteria of (1) isolated unicompartmental osteoarthritis, (2) passively correctable angular deformity, and (3) a fixed-flexion deformity $<10^\circ$ to be considered eligible for UKA. Only medial UKA procedures were included to ensure uniformity of the operative exposure and technique. Revision procedures were excluded. The minimum follow-up period was 16 weeks. A total of 839 procedures met final inclusion criteria.

Data Retrieval

Demographic information included (1) age, (2) gender, and (3) body mass index (BMI). Technical specifications included (1) side of operation, (2) suture used for wound closure, and (3) operative time. Documented risk factors for infection were (1) smoker status, (2) diabetes mellitus, (3) renal insufficiency, and (4) immunosuppressant medications or immunocompromised state [12,13,15,16]. Data were retrieved from the institutional electronic medical record system (Allscripts Sunrise 6.1; Allscripts, Chicago, IL).

Outcomes of interest were superficial (relative to the arthrotomy) or deep infection (confirmed intraoperatively by peri-prosthetic purulence, sinus tracts in communication with the prosthesis and/or positive joint cultures) [17]. Cases were identified from the surgical log of the senior author (A.D.P.). Supplementary information for cases included (1) presenting symptoms (2) time from index procedure to symptom manifestation, (3) intraoperative diagnosis, (4) microbiology cultures, and (5) operative intervention.

Surgical Procedure

All UKA procedures were performed by a single surgeon (A.D.P.), using a robot-assisted platform (MAKO Tactile Guidance System; MAKO Surgical Corporation, Fort Lauderdale, FL). A medial fixed-bearing implant was placed after tibial and femoral resurfacing. Patients received either a RESTORIS MCK Onlay or RESTORIS MCK Medial Unicondylar Inlay tibial component (MAKO Surgical Corporation). All surgeries were performed in an inpatient setting at the same hospital, with a variable length of stay based on pain and functional ambulation status. Each patient received a single intravenous (IV) dose of preoperative antibiotics and 2 IV doses postoperatively.

Wound Closure

Patients were retrospectively assigned to 1 of the 2 cohorts, in which barbed (cohort 1) or conventional (cohort 2) suture was used. Cohorts were subdivided on the basis of variations in closure (Table 1).

Table 1
Closure Technique Cohorts.

Cohort	Closure Layer		
	Arthrotomy	Subcutaneous	Skin
1A (n = 89)	Quill #2 PDO	Vicryl 2-0	Quill 2-0 Monoderm
1B (n = 244)	Vicryl #0	Vicryl 2-0	Quill 2-0 Monoderm
2A (n = 243)	Vicryl #0	Vicryl 2-0	2-0 Monocryl
2B (n = 263)	Vicryl #0	Vicryl 2-0	Skin staples

Table 2
Patient Demographics and Risk Factors.

Cohort	Traditional (n = 506)	Barbed (n = 333)	P Value
Age	63.71 ± 10.37	64.31 ± 9.71	.395
Gender (F, M)	239, 267	155, 178	.845
BMI	29.68 ± 5.36	29.38 ± 5.30	.440
Operative time (min)	100	91	<.001
Smoker, active (%)	6.5	2.7	.014
Smoker, former (%)	18.9	33.6	<.001
Diabetes mellitus (%)	7.1	6.9	.915
Renal insufficiency (%) ^a	1.0	0.6	.566
Immunosuppressed or immunocompromised (%)	6.7	7.2	.775
Wound complications (%) ^a	0.0	2.4	<.001

F, female; M, male; BMI, body mass index.

^a Denotes use of Fisher's exact test due to group size ≤ 5 .

Deep closure in cohort 1A was performed with Quill #2 PDO (Surgical Specialties Corporation, Wyomissing, PA). The subcutaneous layer was closed with interrupted 2-0 Vicryl (Ethicon Inc, Somerville, NJ). Subcuticular closure was performed with Quill 2-0 Monoderm (Surgical Specialties Corporation). Dermabond (Ethicon US, Somerville, NJ) was then applied to the incision. Closure of the arthrotomy and skin with Quill was performed in a running bidirectional fashion away from the incision midpoint. Stitches were doubled back and cut flush with the layer of closure.

Conventional closure in cohort 2A began with interrupted Vicryl #0 (Ethicon Inc) in the deep layer. The subcutaneous layer was closed with interrupted 2-0 Vicryl. Running subcuticular closure was performed with 2-0 Monocryl (Ethicon Inc). Dermabond was applied to the incision site.

In cohort 1B, interrupted Vicryl #0 was used for arthrotomy closure. Closure of the subcutaneous and subcuticular layers proceeded in a manner identical to that of cohort 1A. In cohort 2B, skin closure was performed with staples. Dermabond was not applied to the incision site. Closure of the arthrotomy and subcutaneous layers proceeded in a manner identical to that of cohort 2A.

A nonadherent TELFA island dressing (Medline Industries, Mundelein, IL) nested inside a Tegaderm film (3M Company, St. Paul, MN) was used to cover small incisions overlying the femur and tibia. The primary incision was dressed with Medipore soft cloth surgical tape (3M Company). Dressings were removed on postoperative day 2.

Statistical Analysis

Demographic, technical, and risk variables were compared between groups (cohort 1 vs cohort 2) to detect confounding effects. Means with standard deviation were reported for all continuous variables and compared using independent 2-tailed *t* tests. Categorical variables were reported as frequencies per population and compared by chi-square analysis. Fisher's exact test was used when groups contained 5 or fewer subjects.

Binary logistic regression with Firth's penalized likelihood approach was used to generate odds ratios (ORs) with post-operative wound infection as the outcome of interest. Regression corrected for (1) age, (2) gender, (3) BMI, (4) smoker status, (5) diabetes mellitus, (6) renal insufficiency, (7) immune deficiency, and (8) operative time. ORs were reported with 95% confidence intervals (CIs). Subgroup analysis was performed for variables found to be significant using Fisher's exact test. All tests were conducted at a significance threshold of $P < .05$ using SPSS, version 21 (SPSS Inc, IBM Corporation, Armonk, NY).

Results

Preoperative Demographics and Risk Factors

Of 839 UKA procedures included, 506 used conventional suture, and 333 used barbed suture for wound closure. No differences were detected between the conventional and barbed suture cohorts in age ($P = .395$), gender ($P = .845$), or BMI ($P = .440$). No differences were observed in the frequency of diabetes mellitus ($P = .915$), renal insufficiency ($P = .566$), or immune deficiency ($P = .775$). The conventional suture group contained a higher proportion of active smokers (6.5%) compared with the barbed suture cohort (2.7%; $P = .014$) but a lower frequency of former smokers (18.9% vs 33.6%, respectively; $P < .001$). Barbed suture was associated with a 9-minute reduction in mean operative time ($P < .001$; Table 2).

Wound Complication Cases

Eight cases of postoperative wound infection were identified, all of which used Quill suture for skin closure. Quill was also used for

deep closure in 2 of the cases (Table 3). The mean patient age was 63.0 years (range, 55.2–72.8 years). Six cases occurred in males, and 2 occurred in females. The mean patient BMI was 28.6 (range, 23.6–38.4). Five of the index procedures were performed on the left side.

There were 7 superficial infections that were associated with draining sinus tracts. In 6 of these cases, a deep infection was also documented. In 4 of the 6 cases with a sinus tract and deep infection, the deep infection appeared to be secondary to development of the sinus tract with an occult breach of the arthrotoomy closure (patients 3–6, Table 3). In each of these cases, Quill suture was used for subcuticular closure, and interrupted Vicryl was used for the arthrotoomy closure (cohort 1B). In the remaining 2 cases with a sinus tract, superficial infection was accompanied by an obvious arthrotoomy dehiscence (patients 1–2, Table 3). Both patients received Quill #2 polydioxanone (PDO) for arthrotoomy closure (cohort 1A). One subject experienced a deep infection with no sinus tract, possibly originating from a prior anterior cruciate ligament reconstruction (patient 7, Table 3).

All patients underwent successful treatment with irrigation and debridement, 6 weeks of IV antibiotics, and 6 months of oral

Table 3
Postoperative Wound Infections.

PT	Age	Gender	BMI	Side	Skin Suture	Deep Suture	Onset (d)	Initial Presentation	Intraoperative Findings	Cultures	Risk Factors
1	66	F	27.2	L	Quill 2-0 Monoderm	Quill #2 PDO	12	Serous drainage from anterior aspect of wound after local trauma. Failed Keflex, continued to express purulent drainage.	Arthrotoomy dehiscence, superficial infection (with draining sinus tract)	<i>S aureus</i>	None
2	68	M	27.4	L	Quill 2-0 Monoderm	Quill #2 PDO	8	Drainage from inferior aspect of wound.	Arthrotoomy dehiscence, superficial infection (with draining sinus tract)	<i>P acnes</i>	Former smoker
3	65	M	38.4	R	Quill 2-0 Monoderm	Vicryl #0	20	Central region of wound remained patent with persistent purulent drainage. Persisted despite Keflex.	Deep and superficial infection (with draining sinus tract)	<i>S aureus</i>	None
4	60	M	25.4	L	Quill 2-0 Monoderm	Vicryl #0	19	Serosanguineous drainage from proximal aspect of wound, did not improve with Keflex. Experienced pain and swelling subsequently.	Deep and superficial infection (with draining sinus tract)	(1) <i>S capitis</i> (2) <i>P acnes</i> (3) <i>S aureus</i>	None
5	59	M	25.8	R	Quill 2-0 Monoderm	Vicryl #0	39	Erythema and purulent discharge. Wound remained open in single area, which remained distended and eventually opened. Drainage persisted despite Keflex.	Deep and superficial infection (with draining sinus tract)	<i>S aureus</i>	None
6	55	M	34.7	L	Quill 2-0 Monoderm	Vicryl #0	47	Popped bump on inferior aspect of wound, which resulted in serosanguineous drainage with white granular discharge. MRI revealed sinus tract continuous with deep joint.	Deep and superficial infection (with draining sinus tract)	<i>S epidermidis</i> (methicillin resistant)	None
7	57	M	23.6	L	Quill 2-0 Monoderm	Vicryl #0	26	Severe knee pain causing difficulty ambulating and low-grade fever. Effusion noted, aspiration revealed cloudy fluid from prepatellar bursa.	Deep infection (no sinus tract)	<i>Staphylococcus lugdunensis</i>	None
8	73	F	26.0	R	Quill 2-0 Monoderm	Vicryl #0	22	Purulent discharge from superior aspect of wound. Proximal erythema and induration present. Persisted after amoxicillin and Keflex.	Superficial abscess (with sinus tract)	<i>S aureus</i>	(1) Former smoker (2) Plaquenil for RA, Sjogren syndrome

BMI, body mass index; F, female; L, left; M, male; *P. acnes*, *Propionibacterium acnes*; PDO, polydioxanone; PT, Patient; R, right; RA, rheumatoid arthritis; *S. aureus*, *Staphylococcus aureus*; *S. capitis*, *Staphylococcus capitis*; *S. epidermidis*, *Staphylococcus epidermidis*.

Table 4
Risk Analysis After Binary Logistic Regression.

Variable	Odds Ratio	Lower Limit (95%)	Upper Limit (95%)	P Value
Age	0.982	0.910	1.058	.5696
Gender	2.657	0.665	14.509	.1391
Body mass index	0.981	0.826	1.119	.7667
Smoking	0.658	0.122	2.350	.4959
Diabetes	2.422	0.239	13.902	.3182
Renal insufficiency	9.026	0.051	231.022	.2130
Immunosuppressed or immunocompromised	1.835	0.199	9.316	.4728
Operative time	0.999	0.998	1.000	.0502
Barbed suture	22.818	2.693	2923.91	.0074

N = 693.

antibiotic therapy. Seven patients underwent exchange of the polyethylene tibial component during irrigation and debridement. The UKA was retained in all cases. The average time from the index procedure to symptom manifestation was 24 days (range, 8–47).

Risk Analysis

Binary logistic regression (N = 693) revealed a positive association between the use of barbed suture and the development of postoperative wound complications after UKA (OR = 22.818, CI = 2.69–2923.91; $P = .0074$). Subgroup analysis revealed no difference in the infection rate between Quill cohorts 1A (2.2%) and 1B (2.5%; $P > .999$). No significant associations were observed between other demographic or risk factors and the frequency of wound complications (Table 4).

Discussion

The objective was to compare the postoperative wound infection risk after UKA with barbed vs conventional suture. The findings demonstrated a significant association between barbed suture and subsequent wound infection (OR = 22.818, CI = 2.69–2923.91; $P = .0074$). We sought to examine whether these results were substantiated by the literature surrounding barbed suture in arthroplasty.

This study is subject to several limitations. First, as a retrospective analysis, subjects were not randomized to closure cohorts or followed prospectively. Patients lost to follow-up or who presented to other institutions for postoperative care may introduce a selection bias. Second, confounding variables not included in the analysis may influence the risk of infection. These include drainage volume, personal hygiene, adherence to postoperative wound care, incision length, and nutrition state [12,13]. Third, one must consider the effect of the surgeon's "learning curve" on outcomes. However, this is unlikely to have influenced the findings as (1) the first infection occurred nearly 5 years after the senior author began performing robot-assisted UKA and (2) only 2 of the 8 infections occurred within the first year that Quill suture was used. Fourth, operative time was significantly less in the barbed suture cohort. It is unlikely, however, that this contributed to the higher complication rate as extended procedure length is a known risk factor for infection in joint arthroplasty [18–20]. Finally, it is not possible at this time to differentiate infectious mechanisms by the level of closure (eg, barbed suture in the deep vs subcuticular layer). Deep dehiscence was noted in 2 patients who received Quill #2 PDO during arthrotomy closure, coinciding with a case series by Wright et al [21] in which 3 extensor repairs using Quill PDO failed after TKA. As subgroup analysis revealed no difference in infection rates between cohorts 1A and 1B, the use of barbed suture for retinacular closure cannot be regarded as an independent risk factor at present.

Prior studies of wound complications linked to barbed suture report mixed results [2,6–14]. This lack of consistency is compounded by heterogeneity in surgical procedures, closure technique, follow-up time, and statistical adjustment for confounding variables. Stratification of studies by layer closure reveals increased infection rates when barbed suture is used in subcuticular tissue (Table 5) [2,12–14]. Six studies (2 randomized controlled trial (RCT) and 4 retrospective) reported no difference in complications when barbed suture was deployed in the deep, intermediate, subcutaneous, and/or subdermal layers [6–11]. In comparison, complication rates were increased in 3 out of 4 studies (2 RCT and 2 retrospective) when barbed suture was used in the subcuticular layer [2,12–14]. Our findings corroborate this trend, in that all 8 cases of infection were associated with Quill suture in subcuticular closure.

Neither RCT in which subcuticular barbed suture was used reported significant differences in complications [13,14]. Both studies were underpowered, having been designed to detect differences in closure time but not complication rates [13,14]. Despite this limitation, the severity of the complications encountered prompted the authors of 1 RCT to discontinue the use of barbed suture [13]. All 4 studies using subcuticular barbed suture were single-surgeon, single-center series, minimizing variability [2,12–14]. The greatest source of inconsistency between studies was in statistical correction for confounding factors. Patel et al [12] recorded smoking status and obesity, but did not compare or adjust for rates between cohorts. Campbell et al [2] performed subgroup analysis of operative time, age, procedure, and comorbidities but similarly did not calculate ORs or adjust for such variables. Although the patients recruited by Sah [14] served as their own controls via the contralateral side, confounding variables were neither accounted not corrected for. Smith et al [13] used a regression model to correct for age, BMI, incision length, and number of physicians involved. To our knowledge, the present study is unique in using logistic regression to correct for known risk factors in the comparison of wound infections after the use of barbed suture in the subcuticular layer.

Several mechanisms have been proposed to explain the development of infection after the use of barbed suture (Fig. 1). First, overtightening of barbed suture may predispose tissue to ischemic necrosis with secondary infection [13,22,23]. This phenomenon has been observed in urologic and plastics procedures, particularly during the initial "learning curve" period [23,24]. Flexion tightens the skin and underlying tissue, particularly in knees closed in extension [25]. Second, suture migration and extrusion may create a portal for contamination as described by Hammond [2,26]. Campbell et al proposed that extrusion is linked to wound mobility, citing a study reporting barb eversion and suture migration under tension at the wound site [2,27]. This is consistent with reports of increased complications in the arm and thigh after body-contouring procedures [28,29]. Wound site motion secondary to early rehabilitation may, therefore, explain the disproportionately increased risk of infection (secondary to barbed suture use) after arthroplasty procedures. This is especially concerning in UKA, where early mobilization is particularly aggressive to promote a rapid return to full function [30]. Finally, some have proposed that barbed suture is prone to infection by virtue of its design. Theories center on the propensity of barbed suture to trap fibers from towels and gauze or to accumulate bacteria in the increased surface area under the barbs [25,26,28,29]. Such mechanisms, however, have yet to be confirmed in vivo.

Infection rates after UKA are typically lower than those of TKA because of less tissue exposure and faster operative time [31]. That UKA infections rose to 2.4% (vs a historic rate of 0.1%–2% in TKA) after the adoption of barbed suture despite such advantages is therefore remarkable [16,32]. UKA may be especially vulnerable to infection through the proposed strangulation and extrusion

Table 5
Literature Review of Barbed Suture in Arthroplasty.

Author	Year	Procedures	Study Type	Conventional Suture					Barbed Suture					Follow Up ^a	Infectious Complications	Barbed Suture in Subcuticular Layer
				Arthrotomy	Fat	Subcutaneous	Subdermal	Subcuticular/Skin	Arthrotomy	Fat	Subcutaneous	Subdermal	Subcuticular/Skin			
Eickmann	2010	178 TKA	Retrospective	#1 Vicryl	—	2-0 Vicryl	—	4-0 Monocryl, skin adhesive	Quill #2 PDO	—	Quill 2-0 PDO	—	Skin adhesive	12 weeks	NSD	No
Stephens	2011	500 TKA	Retrospective	#2 Ti-Cron	—	#0 Vicryl	—	4-0 Monocryl	Quill #2 PDO	—	Quill #0 PDO	—	4-0 Monocryl	Not specified	NSD	No
Ting	2012	35 TKA, 25 THA	Prospective RCT	#1 Vicryl	—	#0 Vicryl	2-0 Monocryl	Staples, skin adhesive	Quill #2 PDO	—	Quill #0 PDO	Quill 2-0 Monoderm	Staples, skin adhesive	12 wk	NSD	No
Gililland	2012	191 TKA	Retrospective	#1 Ethibond	—	—	2-0 Monocryl	Staples	Quill #2 PDO	—	—	Quill #0 PDO	Staples	6 wk	NSD	No
Gililland	2014	394 TKA	Prospective RCT	#1 Ethibond	—	—	2-0 Monocryl	(A) Staples (B) Skin adhesive (C) Adhesive strips	Quill #2 PDO	—	—	Quill 2-0 Monoderm	(A) Staples (B) Skin adhesive (C) Adhesive strips	6 wk	NSD	No
Maheshwari	2015	333 TKA	Retrospective	#1 Ethibond, #0 Vicryl	—	#0 Vicryl, 2-0 Vicryl	—	3-0 Ethilon	#1 Ethibond, Quill #2	—	Quill #0	—	4-0 Monocryl, Staples	24 wk	NSD	No
Patel	2012	150 TKA, 3 UKA, 1 PFA, 121 THA, 4 Hemi	Retrospective	1-0 Vicryl	—	2-0 Vicryl	—	(A) Staples (B) 3-0 Biosyn, skin adhesive/strips	1-0 Vicryl	—	2-0 Vicryl	—	3-0 V-Loc	8 wk	3.9% (staples only) vs 13.0% (barbed); $P = .017$	Yes
Campbell	2014	336 TKA, 80 UKA	Retrospective	#1 Polyglyconate	—	2-0 Vicryl	—	Staples	#1 Polyglyconate	—	2-0 V-Loc	—	3-0 V-Loc	52 wk	7.3% (conventional) vs 19.5% (barbed); $P < .001$	Yes
Smith	2014	80 TKA, 54 THA	Hybrid ^b	#1 Ethibond	#0-Vicryl	2-0 Vicryl	—	3-0 Monocryl	Quill #2	Quill #1	Quill #0	—	Quill 2-0 Monoderm	36 wk	NSD ($P = .40$), but discontinued Quill TKA: 11.5% (conventional) vs 10.5% (barbed) THA: 0% (conventional) vs 8.1% (barbed)	Yes
Sah	2015	100 TKA ^c	Prospective RCT	#1 Vicryl	2-0 Vicryl	2-0 Monocryl	—	3-0 Monocryl	Quill #2	2-0 Vicryl	Quill 2-0 Monoderm	—	Quill 2-0 Monoderm	52 wk	NSD	Yes
Chawla	2015	839 RA-UKA	Retrospective	#0 Vicryl	—	2-0 Vicryl	—	(A) Staples (B) 2-0 Monocryl	(A) Quill #2 PDO (B) #0 Vicryl	—	2-0 Vicryl	—	Quill 2-0 Monoderm	16 wk	0% (conventional) vs 2.4% (barbed); $P < .001$	Yes

Hemi, hip hemiarthroplasty; NSD, no significant difference; PDO = polydioxanone; PFA, patellofemoral arthroplasty; RA-UKA, robot-assisted UKA; RCT = randomized controlled trial; THA, total hip arthroplasty; TKA, total knee arthroplasty; UKA, unicompartmental knee arthroplasty.

^a Standardized in weeks.

^b Prospective RCT (n = 34) with retrospective supplement (n = 100).

^c Bilateral TKA procedures (n = 50).

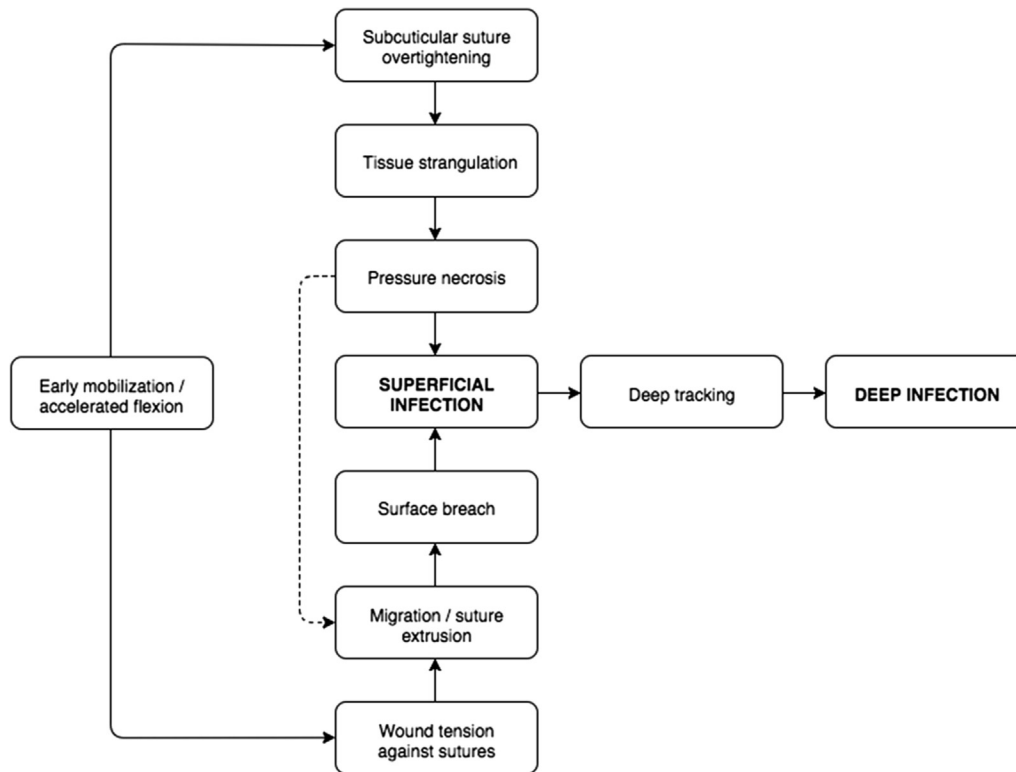


Fig. 1. Proposed infection mechanisms associated with barbed suture. It depicts 2 interacting pathways by which barbed suture may promote wound infection: (1) Overtightening may cause strangulation and ischemic necrosis in the subcuticular layer; (2) Suture may extrude through skin at highly mobile wound sites. Both mechanisms may be accelerated by early postoperative mobilization.

mechanisms as a consequence of early, intensive postoperative mobilization (Fig. 1). Patients often resume 90° flexion and independent ambulation in half the time of TKA patients [33]. Subcuticular necrosis and/or surface skin breaches secondary to overly tight suture and wound tension may permit superficial infection, which can track to the underlying joint. It is ironic that the very characteristic responsible for shorter inpatient stays and quicker recovery in UKA should contribute to the opposite effect by facilitating wound infection [31]. Further in vivo evaluation of barbed suture will ultimately be required to identify and confirm the mechanism of infection.

Conclusions

To our knowledge, this is the first study to assess the risk of postoperative wound complications stemming from the use of barbed suture in a large standardized UKA population. Our findings suggest that barbed suture in subcuticular closure is associated with higher odds of wound infection (OR = 22.818, CI = 2.69–2923.91; $P = .0074$), consistent with the existing literature. Although future studies will be required to identify the specific mechanism of infection, we recommend extreme caution with respect to the use of barbed suture in UKA.

References

- Mansour A, Ballard R, Garg S, et al. The use of barbed sutures during scoliosis fusion wound closure: a quality improvement analysis. *J Pediatr Orthop* 2013;33(8):786.
- Campbell AL, Patrick DA, Liabaud B, et al. Superficial wound closure complications with barbed sutures following knee arthroplasty. *J Arthroplasty* 2014;29(5):966.
- Bautista T, Shabbir A, Rao J, et al. Enterotomy closure using knotless and barbed suture in laparoscopic upper gastrointestinal surgeries. *Surg Endosc* 2015.
- Nguyen D, Szomstein S, Ordonez A, et al. Unidirectional barbed sutures as a novel technique for laparoscopic ventral hernia repair. *Surg Endosc* 2016;30:764.
- Bai Y, Pu C, Yuan H, et al. Assessing the impact of barbed suture on vesicourethral anastomosis during minimally invasive radical prostatectomy: a systematic review and meta-analysis. *Urology* 2015;85(6):1368.
- Eickmann T, Quane E. Total knee arthroplasty closure with barbed sutures. *J Knee Surg* 2010;23(3):163.
- Stephens S, Politi J, Taylor BC. Evaluation of primary total knee arthroplasty incision closure with the use of continuous bidirectional barbed suture. *Surg Technol Int* 2011;21:199.
- Ting NT, Moric MM, Della Valle CJ, et al. Use of knotless suture for closure of total hip and knee arthroplasties: a prospective, randomized clinical trial. *J Arthroplasty* 2012;27(10):1783.
- Gililland JM, Anderson LA, Barney JK, et al. Barbed Versus Standard Sutures for Closure in Total Knee Arthroplasty: A Multicenter Prospective Randomized Trial. *J Arthroplasty* 2014;29:135.
- Gililland JM, Anderson LA, Sun G, et al. Perioperative closure-related complication rates and cost analysis of barbed suture for closure in TKA. *Clin Orthop Relat Res* 2012;470(1):125.
- Maheshwari AV, Naziri Q, Wong A, et al. Barbed sutures in total knee arthroplasty: are these safe, efficacious, and cost-effective? *J Knee Surg* 2015;28:151.
- Patel RM, Cayo M, Patel A, et al. Wound complications in joint arthroplasty: comparing traditional and modern methods of skin closure. *Orthopedics* 2012;35(5):e641.
- Smith EL, DiSegna ST, Shukla PY, et al. Barbed versus traditional sutures: closure time, cost, and wound related outcomes in total joint arthroplasty. *J Arthroplasty* 2014;29(2):283.
- Sah AP. Is there an advantage to knotless barbed suture in TKA wound closure? A randomized trial in simultaneous bilateral TKAs. *Clin Orthop Relat Res* 2015;473(6):2019.
- Slade Shantz JA, Vernon J, Leiter JRS, et al. Sutures versus staples for wound closure in orthopaedic surgery: a randomized controlled trial. *BMC Musculoskelet Disord* 2012;13(1):89.
- Kapadia BH, Berg RA, Daley JA, et al. Periprosthetic joint infection. *Lancet* 2015;6736(14):1.
- Osmon DR, Berbari EF, Berendt AR, et al. Diagnosis and management of prosthetic joint infection: clinical practice guidelines by the Infectious Diseases Society of America. *Clin Infect Dis* 2013;56(1):e1.
- Eggers MD, Fang L, Lionberger DR. A comparison of wound closure techniques for total knee arthroplasty. *J Arthroplasty* 2011;26(8):1251.

19. Dicks KV, Baker AW, Durkin MJ, et al. Short operative duration and surgical site infection risk in hip and knee arthroplasty procedures. *Infect Control Hosp Epidemiol* 2015;36:1431.
20. Zhu Y, Zhang F, Chen W, et al. Risk factors for periprosthetic joint infection after total joint arthroplasty: a systematic review and meta-analysis. *J Hosp Infect* 2015;89(2):82.
21. Wright RC, Gillis CT, Yacoubian SV, et al. Extensor mechanism repair failure with use of bidirectional barbed suture in total knee arthroplasty. *J Arthroplasty* 2012;27(7):1.
22. Liatsikos E, Knoll T, Kyriazis I, et al. Unfavorable outcomes of laparoscopic pyeloplasty using barbed sutures: a multi-center experience. *World J Urol* 2013;31(6):1441.
23. Williams SB, Alemozaffar M, Lei Y, et al. Randomized controlled trial of barbed polyglyconate versus polyglactin suture for robot-assisted laparoscopic prostatectomy anastomosis: technique and outcomes. *Eur Urol* 2010;58(6):875.
24. Moya AP. Barbed sutures in body surgery. *Aesthetic Surg J* 2013;33(3 Suppl): 57S.
25. Rosenberg AG. The use of a barbed suture in hip and knee replacement wound closure. *Semin Arthroplasty* 2013;24:132.
26. Hammond DC. Barbed sutures in plastic surgery: a personal experience. *Aesthetic Surg J* 2013;33(3 Suppl):32S.
27. Helling ER, Okpaku A, Wang PT, Levine RA. Complications of facial suspension sutures. *Aesthetic Surg J* 2007;27(2):155.
28. Shermak MA, Mallalieu J, Chang D. Barbed suture impact on wound closure in body contouring surgery. *Plast Reconstr Surg* 2010;126(5):1735.
29. Hurwitz DJ, Reuben B. Quill barbed sutures in body contouring surgery: a 6-year comparison with running absorbable braided sutures. *Aesthetic Surg J* 2013;33(3 Suppl):44S.
30. Smith TO, Chester R, Glasgow MM, et al. Accelerated rehabilitation following Oxford unicompartmental knee arthroplasty: five-year results from an independent centre. *Eur J Orthop Surg Traumatol* 2012;22(2):151.
31. Bolognesi MP, Greiner MA, Attarian DE, et al. Medicare beneficiaries, 2000 to 2009. *J Bone Joint Surg* 2013;95(22):e174.
32. Gbejuade HO, Lovering AM, Webb JC. The role of microbial biofilms in prosthetic joint infections. *Acta Orthop* 2015;86(2):147.
33. Yang KY, Wang MC, Yeo SJ, et al. Minimally invasive unicompartmental versus total condylar knee arthroplasty—early results of a matched-pair comparison. *Singapore Med J* 2003;44(11):559.